

# Florid cemento - osseous dysplasia- A case report

Poornima Kamatchi P.<sup>1</sup>, Chittilappily Joseph Silvin Joe<sup>2</sup>, Sahithi Varshini D.<sup>3</sup>, Sailakshmi L.J.<sup>4</sup>, Ranjani D.<sup>5</sup>, Nadeem Jeddy<sup>6</sup>

## ABSTRACT

Fibro - osseous lesions are characterized by replacement of normal bone by fibrous tissue containing a newly formed mineralized product. It includes fibrous dysplasia, cemento osseous dysplasia and ossifying fibroma. The authors present a case report of a 40-year-old female patient who experienced dull pain and bone exposure in the lower right posterior region of the mandible. Radiographic examination revealed multiple mixed radiolucent and radiopaque lesions in the mandible. Special staining with Modified Gallego's stain highlighted cementum-like deposits in red. Based on the clinical and radiological findings, the patient was advised to undergo surgical resection. This case report discusses the pathogenesis, histopathological features, and differential diagnosis of the lesion.

**Key words:** fibro osseous lesions, dysplasia, modified Gallego staining, differential diagnosis.

## INTRODUCTION

Fibro-osseous lesions are a group of jaw disorders characterized by the replacement of normal bone with a benign connective tissue matrix that exhibits varying degrees of mineralization. This matrix can range from woven bone to round, acellular, basophilic structures resembling cementum, which are often indistinguishable from cementicles<sup>1</sup>. The first reported case of a fibro-osseous lesion in the head and neck region was documented by Lichtenstein in 1938. Since then, various classification systems have been proposed due to the lack of consensus on diagnostic criteria. In 2017, the World Health Organization (WHO) released a classification of head and neck tumours<sup>2,3</sup>, which categorized cemento-osseous dysplasia (COD) into three distinct subtypes:

1. **Periapical Cemento-Osseous Dysplasia (PCOD)** – typically confined to the anterior mandible, affecting one or more teeth;
2. **Focal Cemento-Osseous Dysplasia (Focal COD)** – presenting as a solitary lesion in the posterior jaws;
3. **Florid Cemento-Osseous Dysplasia (FOCD)** – a widespread form involving multifocal, multi-quadrant lesions that may result in jaw deformity<sup>4</sup>.

An additional classification based on growth potential differentiates non-expansive lesions (including florid, localized, and anterior mandibular variants) from expansive lesions (encompassing both familial and non-familial types)<sup>5</sup>. The pathogenesis of Florid Cemento-Osseous Dysplasia (FCOD), initially described by Melrose, Abrams, and Mills in 1976, is

**Department and Institution Affiliation:** <sup>1,4,5,6</sup>Department of oral and maxillofacial pathology and oral microbiology, Thai moogambigai dental college and hospital, Dr.M.G.R. Educational and Research Institute; <sup>2</sup>Dept of Prosthodontics and Implantology, Thai moogambigai dental college and hospital Dr.M.G.R. Educational and Research Institute; <sup>3</sup>Department of oral medicine and radiology, Thai Moogambigai dental college and hospital, Dr.M.G.R. Educational and Research Institute

**Corresponding Author:** Poornima Kamatchi P., Department of oral and maxillofacial pathology and oral microbiology, Thai moogambigai dental college and hospital, Dr.M.G.R. Educational and Research Institute E-mail: poornimakrishna22@gmail.com

**How to cite the article:** P. P. Kamatchi, Silvin Joe C J, D. S. Varshini, L.J. Sailakshmi, D. Ranjani, Jeddy N. Florid cemento - osseous dysplasia- A case report. *Oral Maxillofac Pathol J* 2026; 17(1); 158-161.

**Source of Support:** Nil

**Conflict of Interest:** None

considered a reactive process involving the alveolar bone. In this condition, the normal bone is replaced by a connective tissue matrix composed of cellular fibrous tissue and a sparsely cellular cementum-like material which replaces the normal bone<sup>6</sup>. Here we report a case of Florid Cemento-Osseous Dysplasia involving the mandible

## CASE PRESENTATION

A forty year old female patient reported to our college with a complaint of replacement of her missing teeth in her lower right side. Patient had history of extraction of teeth in her lower right side before 10 days. The patient had no known

underlying medical conditions. Her family history revealed no significant findings. On Intra oral examination patient presented with the edentulous space from 46 to 48 region. (Fig -1)

On routine radiographic examination, OPG revealed multiple mixed radiolucent and radioopaque lesions involving the posterior region of mandible. It blends with the adjacent normal appearing bone. (Fig -2)

CBCT cross section images of mandible revealed multiple well-defined radiopaque masses with radiolucent border in both right and left posterior regions of the mandible. These masses were surrounded by a thin radiolucent border. (Fig -3)

The provisional diagnosis for this case is osseous dysplasia. In agreement with the patient, a multiple diagnostic incisional biopsy was performed in the mandible under the clinical suspicion of FCOD. Specimens were fixed in formalin and sent to the Pathology Department. No intra-operative and post-operative complications were occurred.

On Gross examination, we received 5 bits of tissue fixed in 10% formalin. They were named as A (0.5 \*0.5 mm), B (0.7\* 0.5mm), C (0.2\*0.5), D (0.5\*1.0mm), E(0.5\*1.0mm). Tissues A&D were greyish white in colour. Tissues B,C&E were whitish in colour with irregular borders. They were firm in consistency and were processed as whole.

Microscopic examination of the hematoxylin and Eosin

stained section revealed fragments of fibrovascular connective tissue exhibiting numerous hematoxyphilic cementum like particles and a few ossifications. Few scattered hemorrhage and mild diffuse chronic inflammatory cell infiltrate is seen. (Fig 4)

Modified Gallego's stain (MG) was first introduced by Gallego in 1954. It has been derived from the modification of Lille's stain which uses the basic reagents such as hematoxylin, carbol fuchsin and aniline blue to stain the hard-tissue components.

In MG stain, enamel stained pink, dentin and bone stained green, while cementum stained red<sup>14</sup>. Thus, we used MG stain to identify the hard tissue components in our case. (Fig 5)

A final diagnosis of Florid Cemento-Osseous Dysplasia (FCOD) was established based on the presence of cementum-like deposits observed with special staining, along with radiographic evidence of lesions on both sides of the mandible. The patient was informed about the proposed management plan, which involved surgical resection accompanied by active, long-term follow-up, including regular clinical and radiographic evaluations.

## DISCUSSION

Cemento osseous dysplasia occurs in tooth-bearing areas of the jaws. It primarily affects black women, middle-aged adults, and the elderly. In 1991, three occurrences involving Caucasian

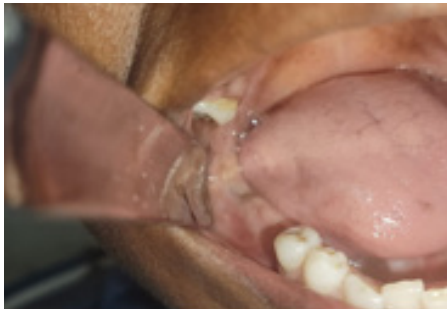

Fig. 1 Intraoral photograph showing edentulous space from 46 region

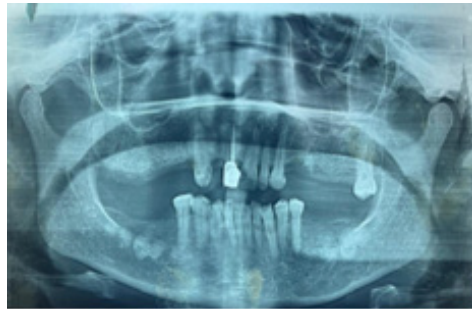

Fig. 2 OPG

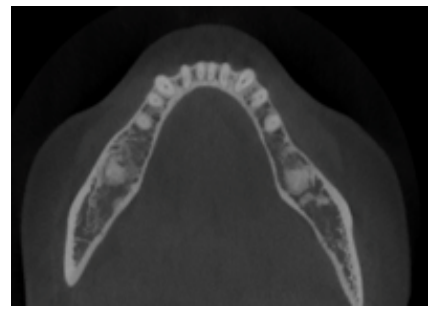


Fig. 3 CBCT

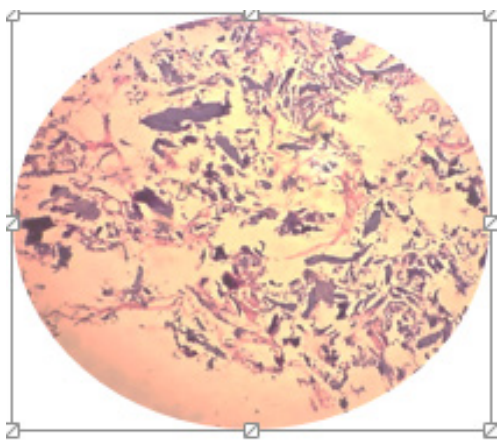


Fig. 4 Histopathological picture (20X) revealed bony spicules and cementum like hard-tissue within cellular fibrous connective tissue.

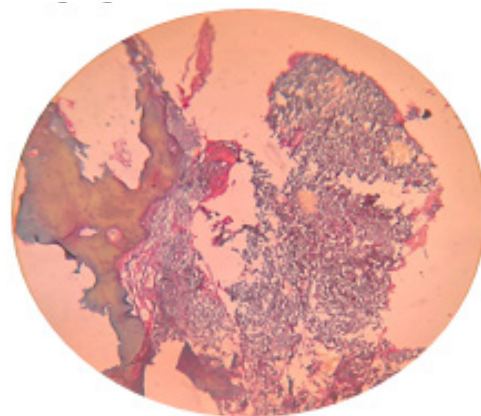


Fig. 5 (10X) Histopathological picture revealed cementum like deposits in red colour and bone in green colour within cellular fibrous connective tissue in MG stain.

family members were noted by Oikarinen et al. Coleman documented comparable lesions in a woman and her two African-descent children in 1996<sup>7</sup>. The reported case was also a female in her middle age.

The pathogenesis of this lesion remains uncertain. According to some researchers, CODs might be a defect in extra-ligamentary bone remodelling triggered by hormone imbalances or local factors<sup>8</sup>. Günhan, Ö, et al (2021) states that the craniofacial bones, in contrast to other bones, originate from the neural crest, so COD may only occur in the jaws.<sup>9</sup> Thus, periodontal mesenchymal cells also have the potential to differentiate into osteoblasts, cementoblasts, and fibroblasts<sup>10,11</sup>.

The Radiographic appearance of FCOD lesion, initially is radiolucent but with time, become mixed then predominantly radiopaque with only a thin peripheral radiolucent rim. The reported case also shows mixed radiolucent and radiopaque lesion with bilateral involvement of mandible that gives a clue to final diagnosis.

MG stain also revealed cementum like deposits within cellular fibrous connective tissue that aids in diagnosis. Thus, final diagnosis was concluded as Florid cemento-osseous dysplasia.

As the chief complaint of our patient was replacement of

missing teeth in her lower right side, a very cautious, methodical implant procedure can be carried out, which can effectively result in the best possible functional rehabilitation<sup>13</sup>.

**CONCLUSION**

This case report emphasizes the importance of accurate diagnosis prior to initiating treatment. In asymptomatic patients, routine clinical examinations, professional prophylaxis, and reinforcement of proper oral hygiene practices are recommended to manage periodontal health and prevent tooth loss. In symptomatic cases, surgical intervention may be required and should be performed under appropriate antibiotic coverage<sup>15</sup>. Due to the reduced vascularity of the affected tissue, dentoalveolar surgical procedures involving FCOD-affected areas carry an increased risk of postoperative complications, such as bone infection. In severe cases, this may progress to bone sequestration, osteomyelitis, or even pathological fractures<sup>13</sup>. Regular follow-up is advised to monitor for malignant transformation.

**Declaration of patient consent**

The authors certify that they have obtained all appropriate patient consent forms. In the form the patient(s) has/have given his/her/their consent for his/her/their images and other clinical information to be reported in the journal. The patients understand that their names and initials will not be published and due efforts will be made to conceal their identity, but anonymity cannot be guaranteed.

**Table 1: Differential diagnosis**

|                | Differential diagnosis;                  | Rule out   |
|----------------|--|--|
| Radiographic   | Odontoma                                 | Well defined localised radio opaque masses may look like miniature teeth which is absent in our case   |
|                | Ossifying fibroma                        | Well-circumscribed, expansile radiolucent to radio opaque lesion which is absent in our case.  |
| Histopathology | Fibrous dysplasia                        | It has a histological feature of bone trabeculae which is not connected to each other. It shows monotonous pattern throughout the lesion rather than haphazard mixture of woven bone, and spheroid particles and absence of cementum like tissue in fibrous stroma, which is absent in our case. |
|                | Paget's disease                          | It was excluded due to absence of mosaic bone pattern and increased osteoclastic activity with absence of cementum liketissues, in our case <sup>8</sup> .   |
|                | Chronic diffuse sclerosing osteomyelitis | It was undoubtedly ruled out due to the absence of sclerotic bone with fibrosis and increased osteoclastic activity in our case <sup>12</sup>  |

**Table 2: Reported cases of FCOD in the literature:**

| Authors                             | Age/Sex  | Site  |
|-------------------------------------|--|---|
| Reema A Sharaf (2024) <sup>16</sup> | 21 yr /F   | Both quadrants of the upper and lower arches  |
| Prashanth Pan-ta et al (2021)       | 2 cases <ul style="list-style-type: none"> <li>• 30yr/F</li> <li>• 50yr /F</li> </ul>                                    | Bilateral involvement of posterior mandible   |
| Choudhary SH et al. (2019)          | 27yr/F   | Bilateral involvement of posterior mandible   |
| Chandramani B. More et al (2012)    | 60yr/F   | Bilateral involvement of posterior maxilla and mandible   |
| Anita Balan et al (2008)            | 4 cases <ul style="list-style-type: none"> <li>• 37yr/F</li> <li>• 40yr/F</li> <li>• 29yr/F</li> <li>• 60yr/F</li> </ul> | First case showed the involvement of three sextants of mandible only, second case showed involvement of four sextants whereas third and fourth cases showed involvement of all the sextants |



## REFERENCES

1. Aiuto, R., Gucciardino, F., Rapetti, R., Siervo, S., Bianchi, A.E.: Management of symptomatic florid cemento-osseous dysplasia: Literature review and a case report. *J Clin Exp Dent.* 10, e291 (2018). <https://doi.org/10.4317/JCED.54577>
2. Speight, P.M., Takata, T.: New tumour entities in the 4th edition of the World Health Organization Classification of Head and Neck tumours: odontogenic and maxillofacial bone tumours. *VirchowsArchiv.* 472, 331–339 (2018). <https://doi.org/10.1007/S00428-017-2182-3/TABLES/3>
3. Zhang, J., Yu, Y., Tang, W., Pan, J., Jing, W.: Cemento-Osseous Dysplasia: A Detailed Comparison of the 2005 and 2017 WHO Classifications and Case Analysis. *Cureus.* 15, e49041 (2023). <https://doi.org/10.7759/CUREUS.49041>
4. Toledano-Serrabona, J., Núñez-Urrutia, S., Vegas-Bustamante, E., Sánchez-Torres, A., Gay-Escoda, C.: Florid cemento-osseous dysplasia: Report of 2 cases. *J Clin Exp Dent.* 10, e1145 (2018). <https://doi.org/10.4317/JCED.55288>
5. Brody, A., Zalatnai, A., Csomo, K., Belik, A., Health, C.D.-N.-B.O., 2019, undefined: Difficulties in the diagnosis of periapical translucencies and in the classification of cemento-osseous dysplasia. SpringerA Brody, A Zalatnai, K Csomo, A Belik, C Dobo-NagyBMC Oral Health, 2019•Springer. 19, (2019). <https://doi.org/10.1186/s12903-019-0843-0>
6. Decani, S., Quatralo, M., Costa, D., Moneghini, L., Varoni, E.M.: Florid cemento-osseous dysplasia: A case report and review of literature. *Heliyon.* 10, e33746 (2024). <https://doi.org/10.1016/J.HELIYON.2024.E33746>
7. Fenerty, S., Shaw, W., Verma, R., Syed, A.B., Kuklani, R., Yang, J., Ali, S.: Florid cemento-osseous dysplasia: review of an uncommon fibro-osseous lesion of the jaw with important clinical implications. *Skeletal Radiology* 2017 46:5. 46, 581–590 (2017). <https://doi.org/10.1007/S00256-017-2590-0>
8. Neville, B.W., Damm, D.D., Allen, C.M. and Chi, A.C. (2016) *Oral & Maxillofacial Pathology.* 4th Edition, WB Saunders, Elsevier, Missouri.
9. Günhan, Ö., Kahraman, D., Yalçın, Ü.K.: The possible pathogenesis of cemento-osseous dysplasia: A case series and discussion. *Advances in Oral and Maxillofacial Surgery.* 3, 100105 (2021). <https://doi.org/10.1016/J.ADOMS.2021.100105>
10. Achilleos, A., Trainor, P.A.: Neural crest stem cells: discovery, properties and potential for therapy. *Cell Res.* 22, 288–304 (2012). <https://doi.org/10.1038/CR.2012.11>
11. Waldron, C.A.: Fibro-osseous lesions of the jaws. *Journal of Oral and Maxillofacial Surgery.* 43, 249–262 (1985). [https://doi.org/10.1016/0278-2391\(85\)90283-6](https://doi.org/10.1016/0278-2391(85)90283-6)
12. Mehta: Floridcemento-osseousdysplasia: A case report - Google Scholar, [https://scholar.google.com/scholar\\_lookup?journal=Indian%20Dent%20Res%20Rev&title=Floridcemento-osseousdysplasia:%20A%20case%20report&author=RV%20Mehta&author=S%20Khan&volume=3&publication\\_year=2011&pages=22-3&](https://scholar.google.com/scholar_lookup?journal=Indian%20Dent%20Res%20Rev&title=Floridcemento-osseousdysplasia:%20A%20case%20report&author=RV%20Mehta&author=S%20Khan&volume=3&publication_year=2011&pages=22-3&)
13. Esfahanizadeh, N., Yousefi, H.: Successful Implant Placement in a Case of Florid Cemento-Osseous Dysplasia: A Case Report and Literature Review. *Journal of Oral Implantology.* 44, 275–279 (2018). <https://doi.org/10.1563/AAID-JOI-D-17-00140>
14. Afroze SN, Ramulu S, Rao GV, Taneeru S, Bashamalla R, Vadla P. Demystifying the nature of hard tissues in odontogenic tumors using Modified Gallego's stain: A preliminary study. *J Oral Maxillofac Pathol.* 2018 Sep-Dec;22(3):448. doi: 10.4103/jomfp.JOMFP\_33\_18. PMID: 30651705; PMCID: PMC6306605.
15. Olgac, V., Sinanoglu, A., ... F.S.-J. of S., 2021, undefined: A clinicopathologic analysis of 135 cases of cemento-osseous dysplasia: To operate or not to operate? Elsevier.
16. Reema A Sharaf. Florid Cemento Osseous Dysplasia: A Case Report, *J Res Med Dent Sci,* 2024, 12 (01): 038-040